

# Color Atlas of Veterinary Anatomy

VOLUME 2

SECOND EDITION

# The Horse

Raymond R. Ashdown

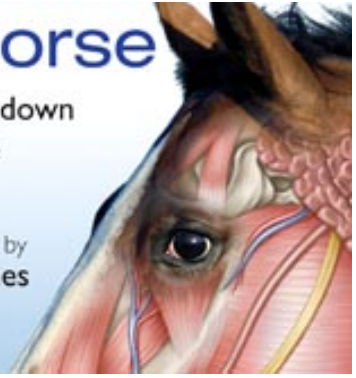
Stanley H. Done

Photography by

Susan A. Evans

Radiographs Provided by

Elizabeth A. Baines

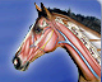

Color Atlas of Veterinary Anatomy  
The Horse

SECOND EDITION  
VOLUME 2

Home

Help



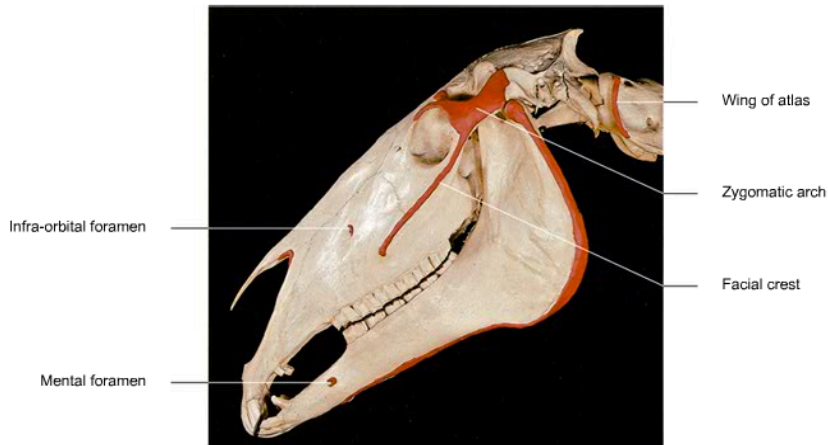
Exit

The Head

Attempts: ■■■

Drag and drop the labels to their correct location:

Mental foramen | Infra-orbital foramen | Zygomatic arch | Wing of atlas | Facial crest



Show Answer

Score 000 104

1 | 2 | 3 | 4 | 5



Pages - 002 - 020



Color Atlas of Veterinary Anatomy  
The Horse

SECOND EDITION  
VOLUME 2

Home

Help

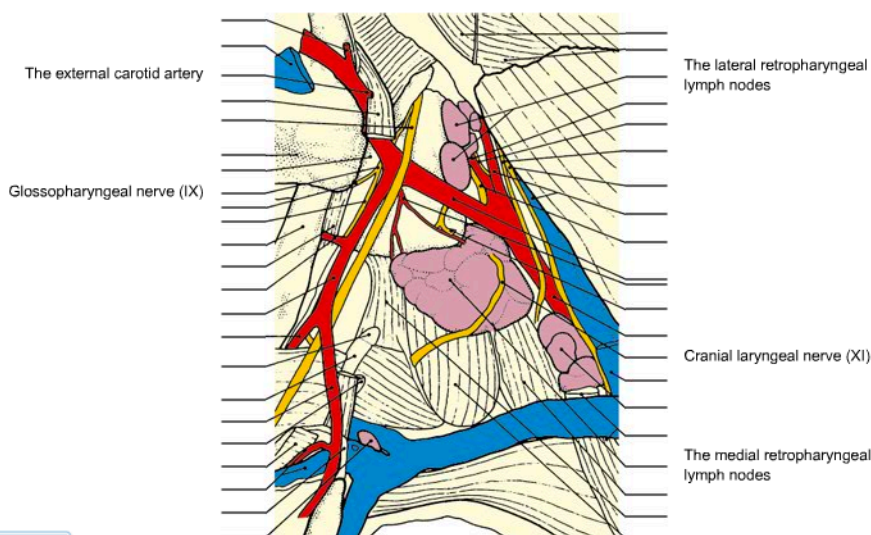


Exit

The Head

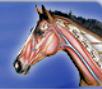Attempts: ■■■

Drag and drop the labels to their correct location:



- The lateral retropharyngeal lymph nodes
- The medial retropharyngeal lymph nodes
- The external carotid artery
- Cranial laryngeal nerve (XI)
- Glossopharyngeal nerve (IX)

Show Answer



The Neck

Attempts: ■ ■ ■

▶ Drag and drop the labels to their correct location:

Labels on the left side of the image:

- Transverse processes of cervical vertebrae
- Major tuberosity of humerus

Labels on the right side of the image:

- Dorsal border of scapular cartilage
- Spine of scapula
- Deltoid tuberosity of humerus
- Olecranon
- Lateral epicondyle of humerus
- Lateral tuberosity of radius

List of items to be dragged (on the right):

- Transverse processes of cervical vertebrae
- Spine of scapula
- Dorsal border of scapular cartilage
- Major tuberosity of humerus
- Deltoid tuberosity of humerus
- Olecranon
- Lateral epicondyle of humerus
- Lateral tuberosity of radius

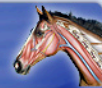Show Answer

Score 000 064

< 1 | 2 | 3 | 4 | 5 >



Pages - 001 - 010



The Neck

Attempts: ■ ■ ■

▶ Drag and drop the labels to their correct location:

Labels on the left side of the image:

- Transverse processes of cervical vertebrae
- Major tuberosity of humerus

Labels on the right side of the image:

- Dorsal border of scapular cartilage
- Spine of scapula
- Deltoid tuberosity of humerus
- Olecranon
- Lateral epicondyle of humerus
- Lateral tuberosity of radius

List of items to be dragged (on the right):

- Transverse processes of cervical vertebrae
- Spine of scapula
- Dorsal border of scapular cartilage
- Major tuberosity of humerus
- Deltoid tuberosity of humerus
- Olecranon
- Lateral epicondyle of humerus
- Lateral tuberosity of radius

Show Answer

Score 000 064

< 1 | 2 | 3 | 4 | 5 >



Pages - 001 - 010

